

Received: 2010.06.14  
Accepted: 2010.10.26  
Published: 2011.05.01

## Use of fondaparinux in a pregnant woman with pulmonary embolism and heparin-induced thrombocytopenia

### Authors' Contribution:

- A** Study Design
- B** Data Collection
- C** Statistical Analysis
- D** Data Interpretation
- E** Manuscript Preparation
- F** Literature Search
- G** Funds Collection

Michał Cieurzyński<sup>1ABCDEFG</sup>, Krzysztof Jankowski<sup>1ABCDE</sup>, Bronisława Pietrzak<sup>2ABCDE</sup>,  
Natalia Mazanowska<sup>2ABCDE</sup>, Ewa Rzewuska<sup>1EGD</sup>, Robert Kowalik<sup>3E</sup>,  
Piotr Pruszczyk<sup>1ABCDEFG</sup>

<sup>1</sup> Department of Internal Medicine and Cardiology, Medical University of Warsaw, Warsaw, Poland

<sup>2</sup> Department of Obstetrics and Gynaecology, Medical University of Warsaw, Warsaw, Poland

<sup>3</sup> Department of Cardiology, Medical University of Warsaw, Warsaw, Poland

**Source of support:** Departmental sources

### Summary

#### Background:

A serious complication of heparin treatment, heparin-induced thrombocytopenia (HIT) is rarely observed in pregnant women. Drug therapy during pregnancy should always be chosen to minimize fetal risk. The management of HIT in pregnancy represents a medical challenge. Unlike heparins, the anticoagulants used in patients with HIT do cross the placenta, with unknown fetal effects.

#### Case Report:

We present a case of a 24-year-old female presenting for care at 34 weeks of gestation with acute pulmonary embolism treated initially with unfractionated heparin (UFH) and low molecular weight heparin (LMWH), who developed HIT. She was then successfully treated with fondaparinux.

#### Conclusions:

To the best of our knowledge, this is one of the first case reports describing a successful use of fondaparinux in the treatment of HIT in a third-trimester pregnant woman, providing a novel approach for this subset of patients.

#### key words:

heparin-induced thrombocytopenia • pulmonary embolism • pregnancy • fondaparinux

#### Full-text PDF:

<http://www.medscimonit.com/abstract/index/idArt/881753>

#### Word count:

1538

#### Tables:

–

#### Figures:

2

#### References:

22

#### Author's address:

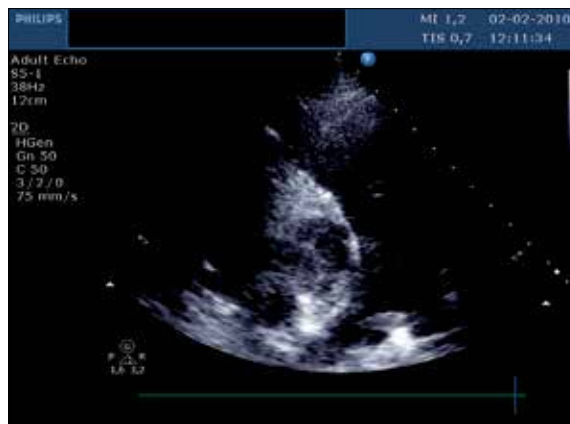
Michał Cieurzyński, Department of Internal Medicine and Cardiology, Medical University of Warsaw, Warsaw, Poland,  
e-mail: [michal.cieurzynski@wum.edu.pl](mailto:michal.cieurzynski@wum.edu.pl)

## BACKGROUND

During pregnancy and the postpartum period, women are 4 times more likely to suffer from venous thromboembolism (VTE) than if they are not pregnant [1]. The incidence of pulmonary embolism (PE) during pregnancy ranges between 0.3 and 1 per 1000 deliveries, and PE is a leading cause of the maternal mortality in developed countries [2,3]. Heparin-induced thrombocytopenia (HIT) is an immune-mediated disorder caused by the development of antibodies to a complex of platelet factor 4 (PF4) and heparin. HIT antibodies of IgG class bind to a multimolecular complex of PF4 and heparin on platelet surfaces, resulting in platelet activation. HIT is reported to be extremely rare in pregnant women. We present a case of a pregnant patient with acute PE treated initially with unfractionated heparin (UFH) and low molecular weight heparin (LMWH), who developed HIT. She was then successfully treated with fondaparinux until delivery.

## CASE REPORT

A 24-year-old female (gravida 1, para 1) at 34 weeks of gestation was referred from another hospital to the Intensive Care Unit due to acute PE. One month before the hospitalization, the patient was prescribed bed-rest due to threatened premature labour. Several days before admission, she fainted and experienced severe dyspnoea. Spiral computed tomography performed in a regional hospital detected bilateral proximal pulmonary artery thromboemboli. Transthoracic echocardiography revealed right ventricular dysfunction – enlarged right ventricle (33 mm), paradoxical movement of the intraventricular septum, McConnell sign, shortened acceleration time (50 ms) and a transtricuspid pressure gradient value of 30 mmHg. Moreover, saddle pulmonary embolus was revealed (Figure 1). On admission to the Intensive Care Unit, she was moderately dyspneic, with preserved systemic blood pressure (110/70 mmHg) and moderate tachycardia 98/min. D-dimer plasma level was 5226 µg/ml (normal values <500 µg/ml, Vidas Bio-Merieux), while plasma cardiac troponin level and renal and hepatic functions were normal. Therefore, a diagnosis of intermediate-risk acute PE was made. Initially, for 4 days the patient was treated with APTT adjusted intravenous infusion of unfractionated heparin (UFH) followed by a 2-day treatment with enoxaparin in a dose of 1 mg/kg. The initial platelet count was  $200 \times 10^9/L$ . Platelet count was monitored every other day during the first days of therapy and always exceeded  $100 \times 10^9/L$ . However, on the seventh day of anticoagulation therapy, a rapid decline in the platelet count, reaching  $44 \times 10^9/L$ , was observed. LMWH was stopped immediately. The following causes of thrombocytopenia in our pregnant patient were considered: heparin-induced thrombocytopenia (HIT), thrombotic thrombocytopenic purpura (TTP), disseminated intravascular coagulation (DIC), preeclampsia-eclampsia and HELLP syndrome. HIT was diagnosed on the basis of antiplatelet-heparin binding antibodies presence in serum (GTI Diagnostics' PF4 Enhanced Solid Phase ELISA), while other causes were excluded. Treatment with subcutaneous fondaparinux injections in a daily dose of 7.5 mg was commenced. Over the next few days, the platelet count decreased further, with a nadir of  $19 \times 10^9/L$ . However, after 10 days the platelet count started to increase progressively (Figure 2). No recurrence of venous thromboembolism



**Figure 1.** Transthoracic echocardiography showing saddle pulmonary thromboembolus.

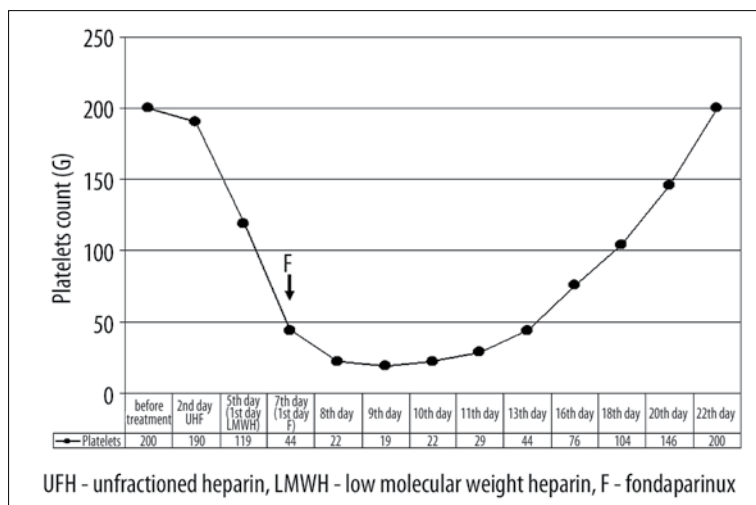
or bleeding occurred. At 37 weeks of gestation, 24 hours before an elective caesarean delivery, fondaparinux injections were discontinued. At that time, platelet count was  $200 \times 10^9/L$  and no signs of right ventricular dysfunction were present on echocardiography. The patient successfully underwent an elective caesarean section under general anesthesia and a healthy female newborn weighting 2620 g was delivered. The course of the surgery was uneventful and no excessive bleeding was observed. Peritoneal drainage and skin closure with interrupted sutures were used as precautionary measures. The newborn suffered from no complications and had a normal platelet count ( $201$  to  $313 \times 10^9/L$ ).

On the first postoperative day, daily fondaparinux injections of 7.5 mg were reintroduced. One day later, the first dose of warfarin was administered and fondaparinux was discontinued 8 days later when a therapeutic INR was maintained between 2 and 3. Both mother and baby were discharged home in good general condition on the 10<sup>th</sup> day after delivery.

## DISCUSSION

VTE in pregnancy is an important cause of maternal morbidity, and acute PE still remains the major cause of maternal mortality in the developed countries [4]. The treatment of acute PE in pregnancy routinely relies on the use of LMWH or UFH. On admission to the hospital, the patient was normotensive, although echocardiographic signs of right ventricular dysfunction were present. According to the recent ESC guidelines on the diagnosis and management of acute pulmonary embolism, our patient suffered from intermediate-risk PE (with a reported short-term mortality of 3–15%) [5]. Anticoagulation with intravenous UFH was initiated, due mainly to fear of possible hemodynamic deterioration, which might have then required thrombolysis or surgical embolectomy. After 4 days of UHF infusion, the patient's hemodynamic status stabilized. Full-dose subcutaneous enoxaparin injections were then started. After 7 days of heparin therapy, the platelet count rapidly decreased from an initial value of  $200 \times 10^9/L$  to  $44 \times 10^9/L$ , and HIT was suspected.

Currently, HIT is diagnosed by the combination of clinical observations and laboratory results. According to the 8th ACCP guidelines on Antithrombotic and Thrombolytic Therapy, diagnosis of HIT should be made when any of the following



**Figure 2.** Medication history. Arrow indicate the day of fondaparinux administration.

events occur in association with the presence of “HIT antibodies” detected by *in vitro* assays: an otherwise unexplained platelet count fall of  $>50\%$ , venous or arterial thrombosis, skin lesions at heparin injection sites, or acute systemic (anaphylactoid) reaction, that occur after iv heparin bolus administration [6]. PF4 ENHANCED enzyme-linked immunosorbent assay confirmed HIT antibodies in the studied patient. It should be noted that we did not perform (14)C-serotonin-release assay, which is regarded for reference method in HIT diagnosis. This test is not widely used in routine clinical practice and was unavailable in our department.

HIT is a rare, but serious side effect, leading to paradoxical thromboembolism. Previous studies have shown that the risk of HIT is lower with LMWH than with UFH, which is more immunogenic, and this condition is extremely rare in pregnant patients [7]. Only 1 possible case of HIT was observed among 1167 pregnancies treated with LMWH in 3 studies [8–10]. Moreover, Greer and Nielson-Piercy reported no HIT cases among 2777 pregnancies in which LMWH was administered [11].

Although patients with HIT can have significantly decreased platelet counts, they still require anticoagulation with an effective antithrombotic agent that does not cross-react *in vivo* with the circulating anti-heparin/PF4 antibodies. Moreover, administration of drug therapy during pregnancy should be very careful to minimise fetal risks. An alternative non-heparin anticoagulant that may be used during pregnancy is danaparoid, which does not appear to cross the placenta [12–14]. Anticoagulation with danaparoid in 2 pregnancies was reported by Schindewolf and Lindhoff-Last [15]. We didn't use danaparoid because this drug was not available in our hospital and it was impossible to use it quickly. Mehta et al described a case of HIT at 7 weeks gestation managed with lepirudin. This agent, however, can cross the placenta [16]. Young et al described a pregnant woman with portal vein thrombosis and thrombocytopenia treated with argatroban for suspected HIT during the third trimester, but there exists only limited human data describing use of this agent during pregnancy [17]. Fondaparinux is another potential therapeutic option for HIT. Fondaparinux offers practical advantages over direct thrombin inhibitors, including once-daily subcutaneous administration, and has no requirement for laboratory

monitoring. However, 1 study found that approximately 10% of the maternal plasma concentration of fondaparinux could be detected in the cord blood of a newborn [18]. Dempfle et al. found transplacental passage of fondaparinux in 5 women, who were treated because of heparin allergy, although this concentration was well below that required for effective anticoagulation, and no adverse effects were noted in the newborns [19]. Furthermore, Lagrange et al observed no transplacental passage of fondaparinux in an *in vitro* study [20]. Finally, Mazollai et al suggest that fondaparinux is a safe and effective treatment in pregnant patients [21]. Importantly, fondaparinux does not cross-react *in vivo* with the circulating anti-heparin/PF4 antibodies, although 1 non-pregnant patient treated with fondaparinux is reported to have developed HIT antibodies in the absence of heparin administration [22].

Since transplacental passage of fondaparinux cannot be excluded, it was decided to perform an elective caesarean delivery in order to minimise the risk of bleeding complications in the newborn during delivery (i.e., intracranial hemorrhage). Moreover, the patient was scheduled for an elective caesarean section because she was diagnosed earlier with threatened preterm labour and had recurrent contractions causing shortening of the cervix. There was considerable concern that it would be necessary to perform an urgent caesarean section without prior discontinuation of fondaparinux, with high risk of bleeding during the surgery. Therefore it was decided to perform an elective caesarean section after the 37<sup>th</sup> week of gestation. We decided to use general anaesthesia due to lack of experience with fondaparinux and regional anaesthesia with the possibility of bleeding complications after neuraxial analgesia. The half-life of fondaparinux is 17–21 h, which means that catheter placement would be possible at least 40 hours (three elimination half-lives) after the last dose of fondaparinux.

## CONCLUSIONS

We believe fondaparinux to be the anticoagulant of choice in rare cases of HIT during the antepartum period. To the best of our knowledge, this is one of the first case reports describing the successful use of fondaparinux in the treatment of HIT in a third-trimester pregnant woman, providing a novel approach for this subset of patients.

**REFERENCES:**

1. Heit JA, Kobbervig CE, James AH et al: Trends in the incidence of venous thromboembolism during pregnancy or postpartum: a 30-year population based study. *Ann Intern Med*, 2005; 36: 697–706
2. Rutherford SE, Phelan JP: Deep venous thrombosis and pulmonary embolism in pregnancy. *Obstet Gynecol Clin North Am*, 1991; 18: 345–70
3. Sullivan EA, Ford JB, Chambers G, Slaytor EK: Maternal mortality in Australia, 1973–1996. *Aust N Z J Obstet Gynaecol*, 2004; 44: 452–57
4. Bates SM, Greer IA, Pabinger I et al: Venous thromboembolism, thrombophilia, antithrombotic therapy, and pregnancy. *Chest*, 2008; 133(Suppl.6): 844S-886S
5. Torbicki A, Perrier A, Konstantinides S et al: Guidelines on the diagnosis and management of acute pulmonary embolism. *Eur Heart J*, 2008; 29: 2276–15
6. Warkentin TE, Greinacher A, Koster A, Lincoff AM: Treatment and prevention of heparin-induced thrombocytopenia: American College of Chest Physician Evidence-Based Clinical Practice Guidelines (8<sup>th</sup> Edition). *Chest*, 2008; 133: 340S–80S
7. Warkentin TE, Levine MN, Hirsh J et al: Heparin-induced thrombocytopenia in patients treated with low-molecular weight heparin or unfractionated heparin. *N Engl J Med*, 1995; 332: 1330–35
8. Sanson BJ, Lensing AW, Prins MH et al: Safety of low-molecular-weight heparin in pregnancy: a systemic review. *Thromb Haemost*, 1999; 81: 668–72
9. Lepercq J, Conrad J, Borel-Derlon A et al: Venous thromboembolism during pregnancy: a retrospective study of enoxaparin safety in 624 pregnancies. *Br J Obstet Gynaecol*, 2001; 108: 1134–40
10. Ellison J, Walker ID, Greer IA: Antenatal use of enoxaparin for prevention and treatment of thromboembolism in pregnancy. *Br J Obstet Gynaecol*, 2000; 107: 1116–21
11. Greer IA, Nelson-Piercy C: Low-molecular-weight heparins for thromboprophylaxis and treatment of venous thromboembolism. *Blood*, 2005; 106: 401–7
12. Chong BH, Magnani HN: Danaparoid for the treatment of heparin-induced thrombocytopenia. In: Warkentin TE, Greinacher A (eds.), *Heparin-induced thrombocytopenia*. 4<sup>th</sup> ed. New York, NY: Informa Healthcare USA, 2007; 319–43
13. Magnani HN, Gallus A: Heparin-induced thrombocytopenia (HIT): a report of 1,478 clinical outcomes of patients treated with danaparoid (Orgaran) from 1982 to mid-2004. *Thromb Haemost*, 2006; 95: 967–81
14. Myers B, Westby J, Strong J: Prophylactic use of danaparoid in high-risk pregnancy with heparin-induced thrombocytopenia-positive skin reaction. *Blood Coagul Fibrinolysis*, 2003; 14: 485–87
15. Schindewolf M, Lindhoff-Last E: Alternative anticoagulation with danaparoid in two pregnancies in a patient with former heparin-induced thrombocytopenia (HIT), homozygous factor V Leiden mutation, a history of venous thrombosis and recurrent pregnancy losses. *Thromb Haemost*, 2008; 99: 776–78
16. Mehta R, Golichowski A: Treatment of heparin induced thrombocytopenia and thrombosis during the first trimester of pregnancy. *J Thromb Haemost*, 2004; 2: 1665–66
17. Young SK, Al-Mandhiry HA, Vaida ST et al: Successful use of argatroban during the third-trimester of pregnancy: case report and review of literature. *Pharmacotherapy*, 2009; 28: 1532–36
18. Harenberg J: Treatment of a woman with lupus and thromboembolism and cutaneous intolerance to heparins using fondaparinux during pregnancy. *Thromb Res*, 2007; 119: 385–88
19. Dampfle CE: Minor transplacental passage of fondaparinux *in vivo*. *N Engl J Med*, 2004; 350: 1914–15
20. Lagrange F, Brun JL, Vergnes MC et al: Fondaparinux sodium does not cross the placental barrier: study using the *in vitro* human dually perfused cotyledon model. *Clin Pharmacokinet*, 2002; 41: 47–49
21. Mazzolai L, Hohlfeld P, Spertini F et al: Fondaparinux is a safe alternative in case of heparin intolerance during pregnancy. *Blood*, 2006; 108: 1569–70
22. Warkentin TE, Maurer RH, Aster RH: Heparin-induced thrombocytopenia associated with fondaparinux. *N Engl J Med*, 2007; 356: 2653–54